

Isabel Martinez-Tejada^{1,2}, Alexander Arum¹, Jens E. Wilhjelm², Marianne Juhler¹ and Morten Andresen¹

¹Department of Neurosurgery, Rigshospitalet, Blegdamsvej 9, DK-2100, Copenhagen Ø

²Department of Health Technology, Technical University of Denmark, Building 349, DK-2800, Kongens Lyngby

Introduction

- B waves in intracranial pressure (ICP) were first described by Lundberg in 1960. These classical B wave patterns continue to be seen in the intensive care unit (ICU) setting and in severe disease states. Less prominent waveforms categorized as B waves appear today as patients undergo ICP monitoring for milder degrees of disease.
- Today's B waves differ in amplitude and visual appearance from those defined by Lundberg, and they usually appear in an irregular pattern. Current diverging waveform definitions fail to adequately describe these patterns seen in daily clinical practice and hamper efforts to automate B wave detection.
- We still lack consensus on precise definitions, terminology, amplitude, frequency or origin of B waves. Several competing terms exist, addressing either their probable physiological origin or their physical characteristics. This diverging range of B wave definitions has not yet been formally classified, hindering their automatic identification in diagnostic or therapeutic scenarios.

Objective

To assess the various terms and definitions used to describe classical B waves.

Methods

A literature search was carried out using PubMed/MEDLINE, with the following search terms: *B waves + review filter, slow waves + review filter, ICP B waves, slow ICP waves, slow vasogenic waves, Lundberg B waves, MOCAIP*. A total sum of 816 paper abstracts were preliminarily screened for content relevance. 124 papers were included in the search review.

Results

Terminologies

- A total of 19 terminologies were found to describe B waves. The most common terms being *B waves* and *(ICP) slow waves*.
- The choice of terminology is often related to the ongoing etiology discussion: 22 articles include the word *vasogenic*.

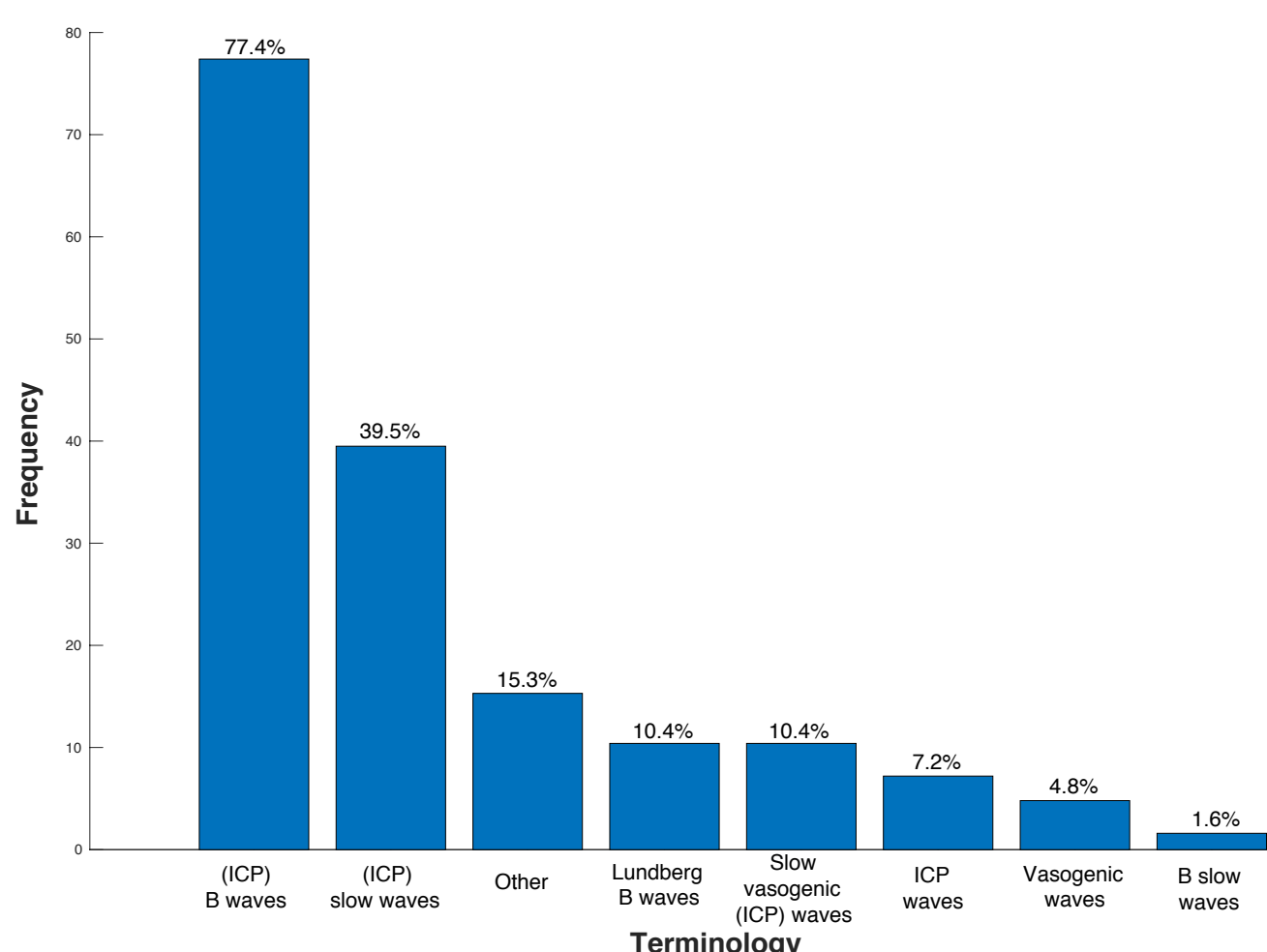


Figure 1. Frequency of terminology usage in the reviewed papers. Terminologies using the same name with/without including the term ICP were grouped as one. No importance was given to the order of words. Hyphens were removed. Terminologies in singular form were registered as plural. Terms used less than three times are included as 'Other.'

Results

Subclassification

- B waves were described using four parameters, which give rise to different subclasses within B waves (Table 1).
- All subclasses fit into the traditional definition of B waves with an extended frequency spectrum, but mainly differ in their morphological characteristics.

	Term	Shape	Plateau	Frequency (waves/min)	Amplitude (mmHg)
Raftopoulos et al. [1]	Small symmetrical wave (SSW)	Symmetrical	No	0.36-5	<10
Santamarta et al. [2]	Great symmetrical wave (GSW)	Symmetrical	No	0.36-5	>10
	Intermediate wave (IW)	Asymmetrical	No	0.33-1.67	6-34
Kasprovicz et al. [4]	Slow symmetrical ICP wave	Symmetrical	No	–	–
	Slow asymmetrical ICP wave	Asymmetrical	No	–	–
	Slow ICP B with plateau phase	Symmetrical	Yes	–	–
Yokota et al. [3]	Type II episodic B-wave	–	–	–	25-75
	Type III persistent, high pressure B-wave	–	–	0.5-2	40-100
	Type IV continuous, regular B-wave	–	–	0.5-2	10-30

Table 1. Major morphological B wave subclasses. B waves were measured based on their shape, presence of plateau, frequency and amplitude. The shape is considered symmetrical if the duration of ascending and descending phases is the same. B waves are categorized into different subclasses if they have distinct shapes and/or if their amplitude is different.

- These sub-classification attempts, which have been mainly qualitative, may be used as supplementary evidence that the classical waveform categories do not adequately address waveforms identified in clinical practice today.
- For instance, IW with the same frequency as symmetrical waves but amplitude similar to plateau waves raise the question whether there is a continuous transition from B waves to plateau waves

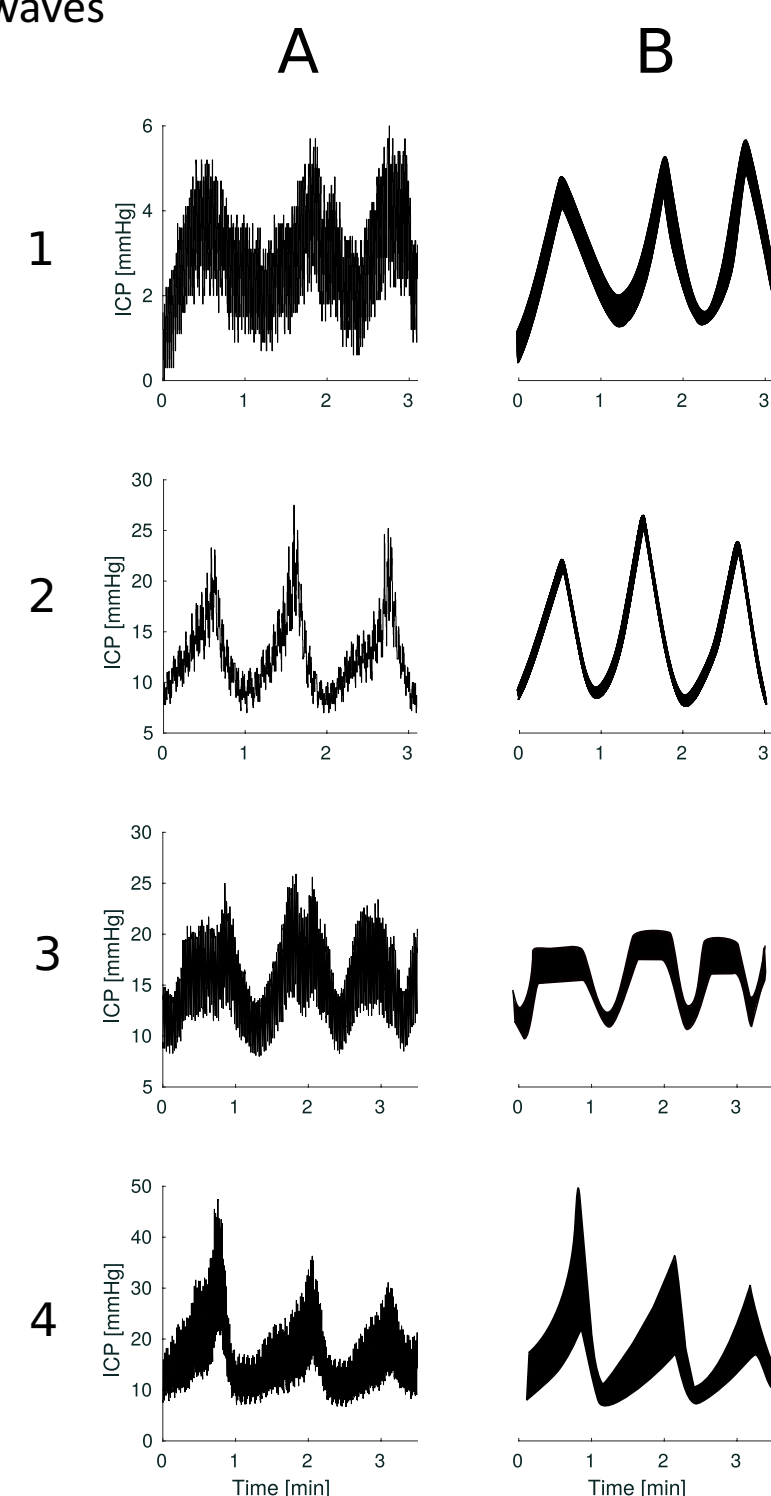


Figure 2. Presentation of different B waves sub-classification patterns. Each is illustrated by two examples: column A from ICP recordings and column B from a theoretical model. Examples on rows 1 and 2 exhibit B waves with symmetrical shape and amplitude lower and higher than 10 mmHg, respectively. Examples of row 3 correspond to symmetrical B waves with plateau. The last row shows examples for asymmetrical B waves.

Conclusion

This study demonstrates the lack of agreement with regard to the terminology and characteristics used to define B waves. Two future lines of action are possible for exploiting the role of macro-patterns in ICP signals and automate their detection:

1. Achieving strict agreement on morphological characteristics of "traditional" A and B waveform.
2. Starting new with a fresh computerized approach for recognition of new clinically relevant patterns.

References

- [1] Raftopoulos C, Chaskis C, Delecluse F, Cantraine F, Bidauti L, Brotchi J. Morphological quantitative analysis of intracranial pressure waves in normal pressure hydrocephalus. *Neurological Research*. 1992;14:389–396.
- [2] Santamarta D, Gonzalez-Martinez E, Fernandez J, Mostaza A. The Prediction of Shunt Response in Idiopathic Normal-Pressure Hydrocephalus Based on Intracranial Pressure Monitoring and Lumbar Infusion. *Acta Neurochir Suppl*. 2016;122:267–274.
- [3] Yokota A, Matsuoka S, Ishikawa T, Kohshi K, Kajiwara H. Overnight recordings of intracranial pressure and electroencephalography in neurosurgical patients. Part I: Intracranial pressure waves and their clinical correlations. *J UOEH*. 1989 Dec;11(4):371–381.
- [4] Kasprovicz M, Bergsneider M, Czosnyka M, Hu X. Association between ICP pulse waveform morphology and ICP B waves. *Acta Neurochir Suppl*. 2012;114:29–34.